

## INTRODUCTION

Fatty liver is the accumulation of triglycerides and other fats in the liver cells. In some patients, this may be accompanied by hepatic inflammation and liver cell death (steatohepatitis). Fatty liver disease is now the most common cause for elevated liver function tests in the United States. Steatosis affects approximately 25-35% of the general population. Steatohepatitis may be related to alcohol-induced hepatic damage or may be unrelated to alcohol (ie, NASH). NASH has been detected in 1.2-9% of patients undergoing routine liver biopsy and NAFLD is found in over 80% of patients who are obese.

NASH can progress to cirrhosis in ~20% of patients. Portal hypertension may subsequently develop and is responsible for many of the more severe consequences of cirrhotic liver disease.

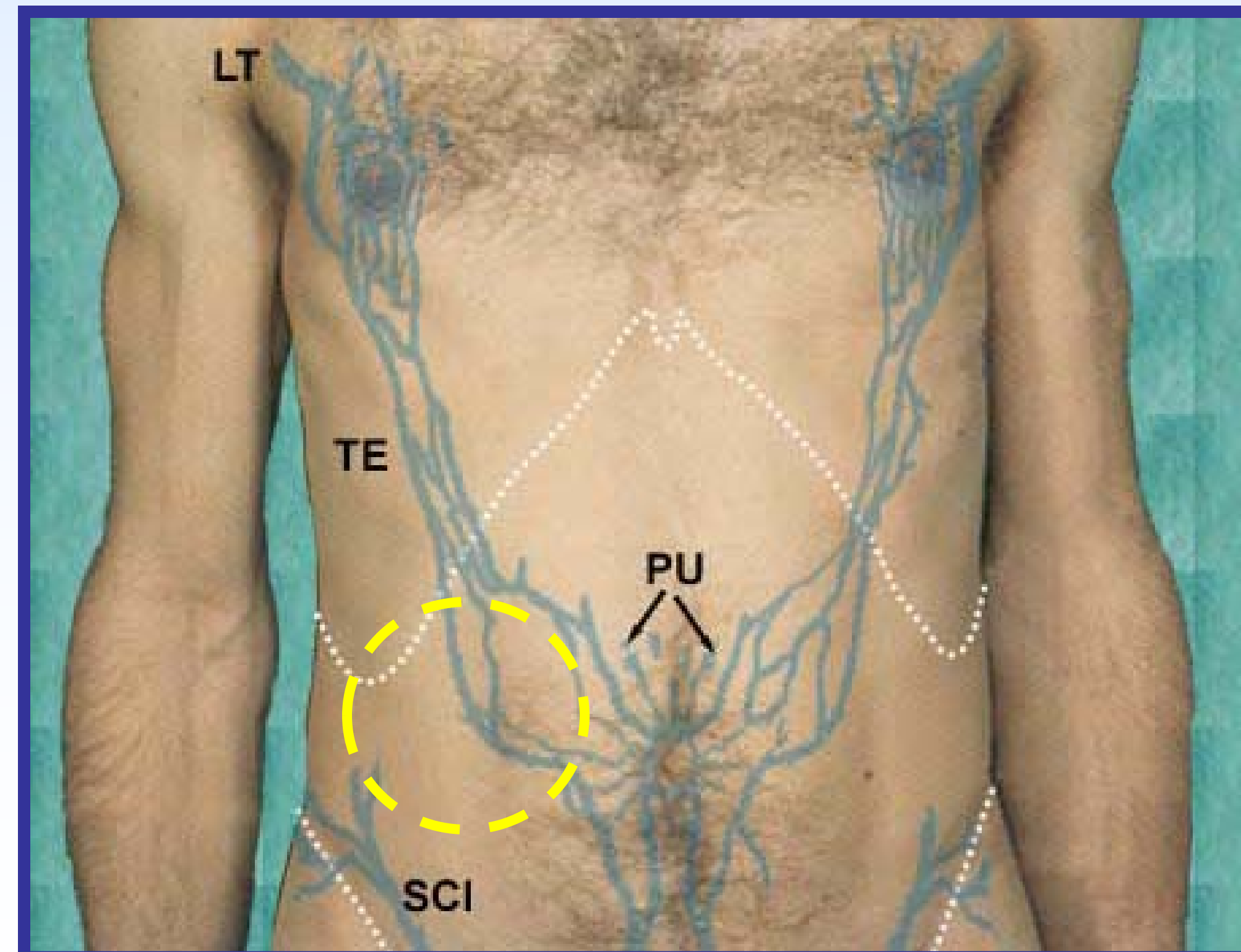
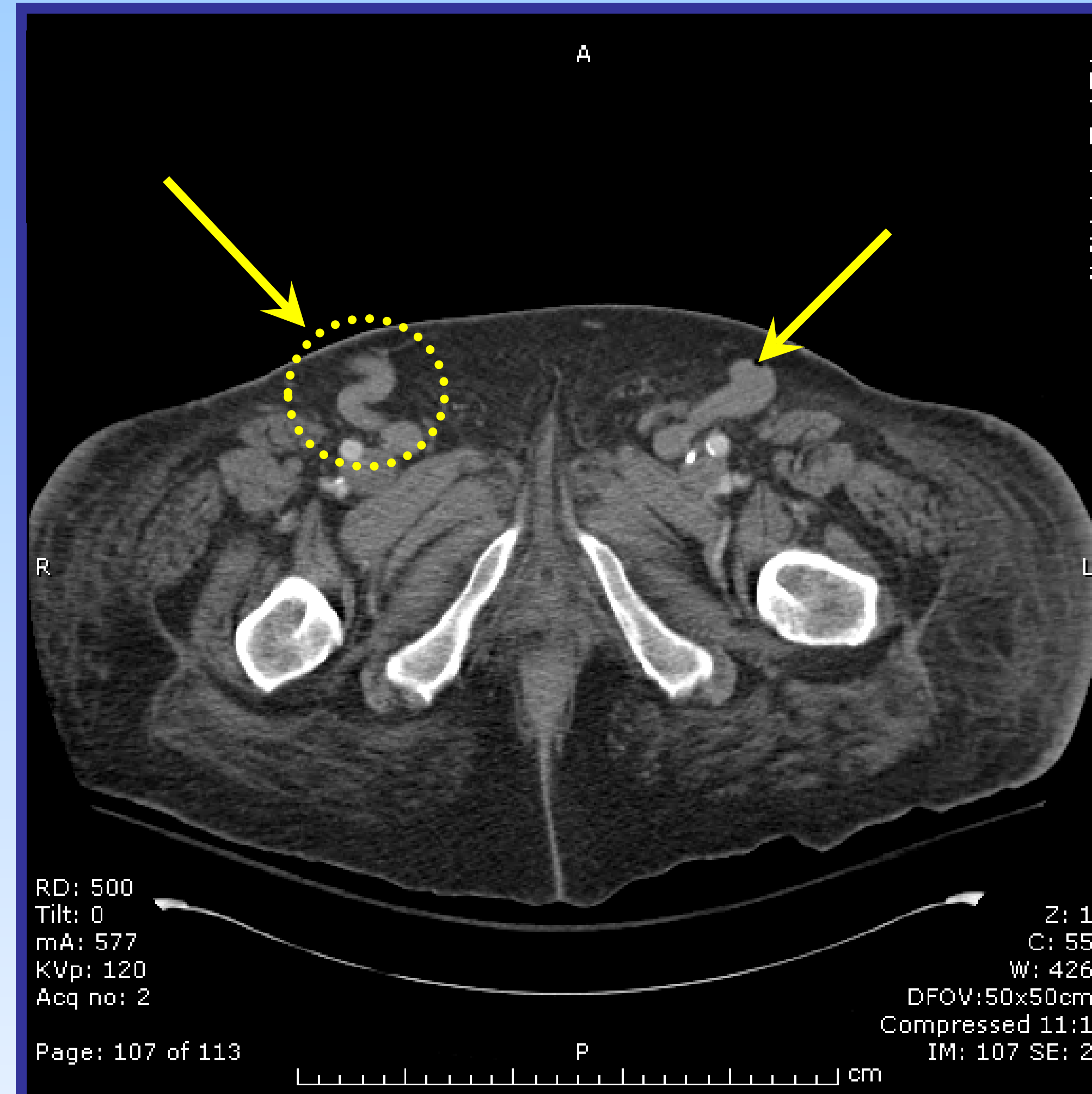
## CASE SUMMARY

A 55 year old gentleman with history of non alcoholic steatohepatitis (NASH), diastolic dysfunction, hypertension, renal insufficiency, gout, descending aortic dissection, COPD, h/o diverticulitis s/p partial colectomy, and morbid obesity presented for routine follow-up and was admitted for an expedited work-up of worsening renal failure. Once admitted, the patient developed an acute episode of peripheral bleeding originating from a spontaneously appearing wound in his RLQ. The patient remained hemodynamically stable throughout this initial episode and hemostasis was achieved with a pressure dressing.

Bleeding later recurred with severe blood loss and hemodynamic instability (Blood pressure 156/73→80/50 mmHg). Hemoglobin decreased from 10.6 to 7.3 despite rapid PRBC transfusion. He was intubated for airway protection and transferred to the ICU for closer monitoring.

CT of his abdomen and pelvis was performed with IV contrast to localize the source of the bleeding and to evaluate for internal hemorrhage given such rapid and severe decompensation. CT revealed several large and dilated paraumbilical veins, one of which had fistulized to the surface of an old colostomy scar. CT also revealed a small nodular liver. The bleeding was stabilized with assistance from trauma surgery and the patient was successfully extubated.

## IMAGES



## DISCUSSION

In cirrhotic patients, portal HTN can develop as a consequence of increased portal venous inflow and increased resistance to portal flow. Common manifestations of portal hypertension include ascites, caput medusae, internal hemorrhoids and esophageal varices.

The literature describes, in several isolated case reports, erosion into dilated paraumbilical veins resulting in massive blood loss. There is often great difficulty in localizing the source of bleeding. This type of bleeding has been particularly described in patients post-colostomy with exsanguination occurring through the stomal opening.

The challenge in this case was to recognize a rare clinical scenario. Often, in decompensating patients, the appropriate clinical course involves emergent surgical exploration. However, in this patient such a course would carry with it high morbidity and mortality making a broader consideration of the differential both necessary and lifesaving. For example, surgery may have resulted in complete laceration of the dilated vein in attempt to open the abdomen for exploration. Furthermore the patient's cirrhosis makes a poor clinical outcome quite likely. In the event of uncontrolled bleeding, embolization by interventional radiology would likely have provided the best outcome.

Childs class	Points	Peri-operative mortality
A	5-6	7-10%
B	7-9	23-30%
C	10-15	75-84%

## REFERENCES

Spier BJ, Fayyad AA, Lucey MR, Johnson EA, Wojtowycz M, Rikkers L, Harms BA, Reichelderfer M. Bleeding stomal varices: case series and systematic review of the literature. *Clin Gastroenterol Hepatol*. 2008 Mar;6(3):346-52.

Bahner JR, Holland RW. Exsanguinating hemorrhage from a caput medusae: cutaneous variceal bleeding. *J Emerg Med*. 1992 Jan-Feb;10(1):19-23.

Mendl J, Krivan F. Acute massive hemorrhage from the recanalized umbilical vein as a complication of portal hypertension. *Rozhl Chir*. 2007 Jun;86(6):303-5.